



Case Report

Subacute Thyroiditis Associated with COVID-19: A Case Report

Om Prakash Mehta^{1,*}, Sumit Rauniyar¹, Muhammad Naeem Afzal¹, Rakshya Upreti²,
Shri Kant Kushwaha³

¹Department of General Medicine, King Edward Medical University, Lahore, Pakistan

²Department of Obstetrics and Gynecology, Paropakar Maternity and Womens Hospital, Kathmandu, Nepal

³Department of Pediatrics, Services Institute of Medical Sciences, Lahore, Pakistan

Email address:

om.mehta72@gmail.com (O. P. Mehta)

*Corresponding author

To cite this article:

Om Prakash Mehta, Sumit Rauniyar, Muhammad Naeem Afzal, Rakshya Upreti, Shri Kant Kushwaha. Subacute Thyroiditis Associated with COVID-19: A Case Report. *International Journal of Diabetes and Endocrinology*. Vol. 6, No. 1, 2021, pp. 54-57.

doi: 10.11648/j.ijde.20210601.19

Received: January 26, 2021; **Accepted:** March 17, 2021; **Published:** March 30, 2021

Abstract: *Background:* Subacute Thyroiditis is a self-limiting thyroidal illness caused by viral infection with clinical course divided into three phases: hyperthyroidism, hypothyroidism followed by euthyroidism. Several viral infections have been linked to be associated with subacute thyroiditis but often no etiology can be found. *Objective:* The aim of this study is to explore a possible link between subacute thyroiditis and Coronavirus disease (COVID-19) infection. *Method:* Here we describe a case of subacute thyroiditis which occurred during the recovery phase of initial flu like illness. The initial illness was mild and was treated symptomatically. Later, the patient presented with features of hyperthyroidism and neck pain during recovery of initial flu like illness. *Result:* Two weeks after the onset of initial illness, the patient presented with neck pain, palpitation, sweating, and weight loss along with mid-line tenderness in neck. Thyroid function test revealed suppressed TSH and elevated free T4 along with reduced uptake on radionuclide thyroid scan. He was treated with NSAIDs and B-blocker which resulted in dramatic improvement in neck pain. *Conclusion:* Since Subacute thyroiditis is a self limiting disorder, it is often under reported. But It is important to recognize the disorder as it can directly impact on the morbidity and mortality related to other associated primary disorder like respiratory illness. Clinician must be aware about the possibility of thyroiditis in patient developing fever and neck pain and look for it.

Keywords: Subacute Thyroiditis, COVID-19, SARS-CoV-2, De Quervain's Thyroiditis

1. Introduction

Subacute thyroiditis (SAT) is a unique type of self-limiting inflammatory destructive thyroiditis with typical presentation and clinical course [1, 2]. SAT is usually preceded by viral infection, but a consistent serologic connection with any one group of viruses has not been demonstrated [1, 3, 4].

In December 2019, Acute respiratory diseases named as Coronavirus Disease 2019 (COVID-19) caused by Severe Acute Respiratory Syndrome Coronavirus 2 (SARS-CoV-2) reported in Wuhan, China. It mainly presented with respiratory illness with fever, cough, difficulty breathing,

and fatigue progressing to Acute Respiratory Distress Syndrome (ARDS) along with various non respiratory symptoms [5, 6]. Several Case reports and case series have been published since then linking COVID-19 to myriad of clinical presentation [6]. Few case reports linking COVID-19 to subacute thyroiditis have also been published [7–10]. Here we present a case of subacute thyroiditis (SAT) linked to COVID-19.

2. Case Report

A 32-year-old male diabetic under treatment and without

personal or family history of thyroid disorder presented with fever, dry cough and malaise on 18 May 2020. Physical examination showed fever of 101.2°F with other vitals being normal. Patient, being a health care professional, was referred for reverse transcriptase- polymerase chain reaction (RT-PCR) for severe acute respiratory syndrome corona virus 2 (SARS-CoV-2) using nasopharyngeal swab. RT-PCR for SARS-CoV-2 was negative on 2 occasions 4 days apart. Chest X-ray postero anterior view was reported as normal. Full blood count showed normal leukocyte count (9900cells/ μ L) with neutrophilia (86% of differential count) and lymphopenia (7% of differential count) and Neutrophil-lymphocyte ratio (NLR) of 12.28. Patient was managed symptomatically with antipyretics and regular monitoring of oxygen saturation, which remained normal throughout the illness, along with bed rest and was advised for home isolation. He had complete resolution of initial symptoms by the end of one week. Two weeks later on 31 May 2020, he again presented complaining of neck pain radiating to the jaw with occasional palpitation, sweating and weight loss. On physical examination he was afebrile with resting pulse rate of 94 beats/ minute and regular. There was midline neck tenderness, non-palpable thyroid and sweating in hands. Rest of the examination was normal. Blood investigation revealed thyrotoxicosis with elevated ESR of 48 mm/hr (reference range less than 30mm/hr). Serological test for SARS-CoV-2 was positive at this time with titer 1.670 (normal cutoff value <1). Thyroid scan using ^{99m}Tc -pertechnetate was done which showed negligible radiotracer uptake within thyroid with increased body background at 20 minutes. He had normal thyroid function test 3 months earlier. He was prescribed Prednisolone 20 mg once daily along with B- blocker. He had dramatic improvement in neck pain but his glycemic control was disturbed in next fasting self-monitoring of blood glucose. So he was switched to NSAIDs, tablet Naproxen 500mg twice daily. Two weeks later he had marked improvement in neck pain along with other symptoms of hyperthyroidism. On last clinic visit, one month after the onset of first neck symptoms, he had neither neck pain nor other symptoms of hyperthyroidism and has been advised for routine follow up.

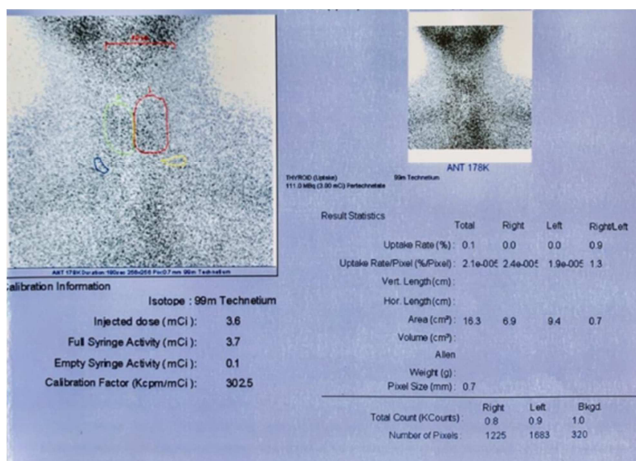


Figure 1. Radionuclide thyroid scan of patient using ^{99m}Tc pertechnetate.

Table 1. Lab investigations.

Laboratory parameters			
Parameters, unit	Reference range	31 May	10 June
FT3, pmol/L	2.5-6	5.7	7.98
FT4, pmol/L	11.5-23.0	24.8	23.3
TSH, mIU/L	0.3-5	0.01	0.02

3. Discussion

SAT, also known as de Quervain's thyroiditis, subacute granulomatous thyroiditis, is a self-recovering, inflammatory, thyroidal disorder caused by possible viral illness [1, 2]. Many viral infection have been linked to development of SAT such as Echovirus, Coxsackie virus, Mumps, Orthomyxovirus, Adenovirus, Hepatitis E, Epstein-Barr virus, HIV, Cytomegalovirus, Dengue fever, Rubella and other viruses [1, 3-4, 7, 11]. It is usually associated with neck pain, general symptoms, and thyroid dysfunction [12]. Neck pain is due to thyroid swelling, which may be confined to one lobe but mostly it spreads rapidly to involve the rest of the gland [12]. The thyroid gland is typically enlarged, smooth, firm and tender to palpation [2]. General symptoms like fever, malaise, fatigue, myalgia and arthralgia are common. A fever as high as 104°F (40.0°C) may occur but usually mild to moderate fever only occur [2, 12]. Patients during the first week of infection presents with symptoms of thyrotoxicosis followed by a state of hypothyroidism and lastly return to euthyroid state, that usually lasts 3 months [7]. A large number of patients have symptoms of thyrotoxicosis, however clinical hypothyroidism is uncommon with our patient also demonstrating features of thyrotoxicosis.

SAT is a clinical diagnosis but laboratory tests and ultrasound are helpful for the diagnosis [7, 12]. Erythrocyte sedimentation rate (ESR) and C-reactive protein are often raised in de Quervain's thyroiditis with ESR raised in our patient. During the thyrotoxic state, TSH is suppressed and free T3 and T4 is raised. In SAT, anti-thyroid peroxidase (TPO-ab) and thyroglobulin (Tg-ab) antibodies are usually present [2, 7]. Radionuclide thyroid scan typically reveals reduced or absent radiotracer uptake within thyroid with similar finding noted in our patients. Ultrasonography reveals heterogenous hypoechoic areas with blurring of margins and poor blood flow on color Doppler [12]. Management of SAT is based on symptoms with some requiring no treatment to NSAIDs for others for control of pain. If patient has poor response to NSAIDs, Prednisolone at a dose of 20-40mg/ day can be initiated with gradual tapering over a period of 6 weeks. However, a study by Duan L et al. comparing short term (1 week) verses long term (6 weeks) prednisolone therapy in patient with SAT found that there were no significant differences between the two groups in terms of efficacy and rate of recurrence. However, short term group experienced less unwanted effects of steroids [13]. A study comparing the effect of NSAIDs and prednisolone in SAT found that the duration required for normalization of thyroid function is similar in patient treated with either NSAIDs or prednisolone. However, prednisolone is superior to NSAIDs with respect to

symptoms resolution [14]. Beta Blocker can be used in initial stage of illness for control of thyrotoxic manifestations but there is no role of antithyroid drugs in management of SAT [2]. The risk of recurrence of SAT may be as high as 20-30% but the exact cause is still unknown. Certain HLA haplotypes such as HLA-B*35 and B 18:01 have been linked to increased risk of recurrence [12].

A study by Rotondi M *et al.* demonstrated the presence of ACE-2 mRNA in thyroidal follicular cells which could lead to direct invasion of thyroid tissue by SARS CoV-2 [15]. Among previous report linking SARS-CoV-2 to de Quervain's thyroiditis, some developed symptoms of thyroiditis during acute phase of illness along with respiratory symptoms while other developing symptoms after recovery of respiratory illness [7–10]. Asfuroglu K E *et al.* in their case report of SAT mentioned symptoms of thyroiditis occurring as a presenting feature of COVID-19 without obvious respiratory symptoms and normal chest X ray and Computed tomography scan of chest but with positive RT-PCR for SARS-CoV-2 in nasopharyngeal swab [9]. Our patient developed symptoms of neck pain and thyrotoxicosis after recovery of initial flu like illness. Of note all previous cases had a positive RT-PCR for SARS-CoV-2 but our patient had negative RT-PCR but with positive serology for SARS-CoV-2 using Electrochemiluminescence immunoassay (ECLIA). We assume SARS-CoV-2 as a precipitant for thyroiditis in our patient because of a temporal relation of flu like illness during COVID-19 pandemic along with positive serology for the virus during symptoms of thyroiditis.

4. Conclusion

COVID-19 has been found to infect multiple organ systems mainly during acute phase of illness with de Quervain's thyroiditis occurring either during acute illness or during recovery of respiratory symptoms. Clinician especially those working in dedicated COVID-19 hospitals should be aware of this potential complication and seek for SAT particularly if patient becomes febrile during recovery of respiratory symptoms.

Abbreviations

SAT: Subacute thyroiditis
 COVID-19: Coronavirus Disease 2019
 SARS-CoV-2: Severe acute respiratory syndrome coronavirus 2
 ESR: Erythrocyte Sedimentation rate
 NSAIDs: Non-steroidal anti-inflammatory drugs
 TSH: Thyroid Stimulating hormone
 FT₃: Free Triiodo Thyronine
 FT₄: Free Thyroxine
 HIV: Human immunodeficiency Virus
 ACE 2: Angiotensin Converting Enzyme 2
 mRNA: messenger RNA

Authors' Contribution

All authors contributed in preparation of manuscript and agree for publication of the final draft of the manuscript.

Consent

Informed written consent is taken from the patient.

Conflict of Interest

All the authors do not have any possible conflicts of interest.

References

- [1] Chiaruzzi M, Arcani R, Mazodier K, Jean R, Weiller P-J, Kaplanski G, *et al.* A Case of Subacute Thyroiditis Associated with Erythrovirus B19 Infection. *Am J Med.* 2020 Jun 1; 133 (6): e296–7.
- [2] Hennessey J v. Subacute Thyroiditis. In: Feingold KR, Anawalt B, Boyce A, Chrousos G, Dungan K, Grossman A, *et al.*, editors. *Endotext* [Internet]. South Dartmouth (MA): MDText.com, Inc.; 2000.
- [3] Bouillet B, Petit J-M, Piroth L, Duong M, Bourg J-B. A Case of Subacute Thyroiditis Associated with Primary HIV Infection. *Am J Med.* 2009 Apr 1; 122 (4): e5–6.
- [4] Desailoud R, Hober D. Viruses and thyroiditis: an update. *Virol J.* 2009 Jan 12; 6 (1): 5.
- [5] Guan W, Ni Z, Hu Y, Liang W, Ou C, He J, *et al.* Clinical Characteristics of Coronavirus Disease 2019 in China. *N Engl J Med.* 2020 Apr 30; 382 (18): 1708–20.
- [6] Mehta OP, Bhandari P, Raut A, Kacimi SEO, Huy NT. Coronavirus Disease (COVID-19): Comprehensive Review of Clinical Presentation. *Front Public Health* [Internet]. 2021; 8.
- [7] Brancatella A, Ricci D, Viola N, Sgrò D, Santini F, Latrofa F. Subacute Thyroiditis After Sars-COV-2 Infection. *J Clin Endocrinol Metab* [Internet]. 2020 Jul.
- [8] Ippolito S, Dentali F, Tanda ML. SARS-CoV-2: a potential trigger for subacute thyroiditis? Insights from a case report. *J Endocrinol Invest.*
- [9] Asfuroglu Kalkan E, Ates I. A case of subacute thyroiditis associated with Covid-19 infection. *J Endocrinol Invest* [Internet]. 2020 Jun 5.
- [10] Ruggeri RM, Campenni A, Siracusa M, Frazzetto G, Gullo D. Subacute thyroiditis in a patient infected with SARS-COV-2: an endocrine complication linked to the COVID-19 pandemic. *Hormones.* 2021 Mar 1; 20 (1): 219–21.
- [11] Siolos A, Terzaki A, Tigas S. Subacute thyroiditis in a patient with Epstein-Barr virus (EBV) meningitis. In *BioScientifica*; 2018.
- [12] Stasiak M, Tymoniuk B, Stasiak B, Lewiński A. The Risk of Recurrence of Subacute Thyroiditis Is HLA-Dependent. *Int J Mol Sci* [Internet]. 2019 Mar 3.
- [13] Duan L, Feng X, Zhang R, Tan X, Xiang X, Shen R, *et al.* Short-Term Versus 6-Week Prednisone In The Treatment Of Subacute Thyroiditis: A Randomized Controlled Trial. *Endocrine Practice.* 2020 Aug 1; 26 (8): 900–8.

- [14] Sato J, Uchida T, Komiya K, Goto H, Takeno K, Suzuki R, et al. Comparison of the therapeutic effects of prednisolone and nonsteroidal anti-inflammatory drugs in patients with subacute thyroiditis. *Endocrine*. 2017 Jan 1; 55 (1): 209–14.
- [15] Rotondi M, Coperchini F, Ricci G, Denegri M, Croce L, Ngniteju ST, et al. Detection of SARS-COV-2 receptor ACE-2 mRNA in thyroid cells: a clue for COVID-19-related subacute thyroiditis. *J Endocrinol Invest* [Internet]. 2020 Oct 6.